



A prospective observational study revealing classification of abnormal uterine bleeding using PALM COEIN: Setting new horizons!

Dr. Surendra¹, Dr. Vinu Choudhary^{2*}

¹ Department of Obstetrics & Gynaecology, S.P. Medical College, Bikaner, Rajasthan, India

² Department of Obstetrics & Gynaecology, SMS Medical College, Jaipur, Rajasthan, India

Abstract

Shoulder pain in athletes is a disabling condition and have several causes. In the pediatric age group, developmental problems during growing skeleton may also give rise to pain associated with apophyseal inflammation. Apophysitis around shoulder region is uncommon. We, hereby, report a case of painful shoulder in an adolescent cricket player that was later diagnosed with acromion apophysitis on clinical and radiological basis and successfully managed by conservative method.

Keywords: shoulder apophysis, painful shoulder, athlete, sports, cricket, acromion, paediatric

Introduction

Abnormal uterine bleeding is a common complaint in women of all ages for which they consult their gynecologist and is the direct cause of a significant health-care burden for women. Abnormal uterine bleeding affects 10%–30% of reproductive age women and 50% of perimenopausal women. The most probable etiology of abnormal uterine bleeding relates to the patients' reproductive age, as does the likelihood of serious endometrial pathology [1,2]. The specific diagnostic approach depends on whether the patient is premenopausal, perimenopausal, or postmenopausal as the endometrium demonstrates a wide spectrum of normal and pathological appearances throughout menarche as well as during the premenopausal and postmenopausal years [3].

Abnormal uterine bleeding is related to:

Changes in frequency of menses (regularity)

Duration of flow (timing)

Amount of blood loss (amount)

Targeted approach is related to age and stage [4].

PALM-COEIN classification of AUB

The classification is based on the acronym “PALM- COEIN”, which stands for Polyp, Adenomyosis, Leiomyoma, Malignancy (and Hyperplasia) and comprises structural pathologies assessed visually. 5 The COEIN group stands for coagulopathy, ovulatory disorders, endometrial, iatrogenic, not otherwise classified and relates to non structural etiologies that cannot be assessed by imaging or histopathology. 5 Leiomyomas (fibroids) are again sub divided, depending on the location, into submucosal (SM) and other (O) and then further into nine categories according to Wamsteker classification.

Aims & objectives

1. To categorize women with AUB according to PALM-COEIN system.

2. A secondary aim was to correlate the clinical diagnosis and pathologic features of various causes of AUB.

Methodology

It was a prospective observational study conducted in dept. of obstetrics & gynaecology at a tertiary care center. Study period was from February 2019 to October 2019. A total of 150 cases were included in the study.

Inclusion criteria

All women of reproductive age groups of year 20-55, suffering from AUB and underwent diagnostic endometrial biopsy were included in the study.

Exclusion criteria

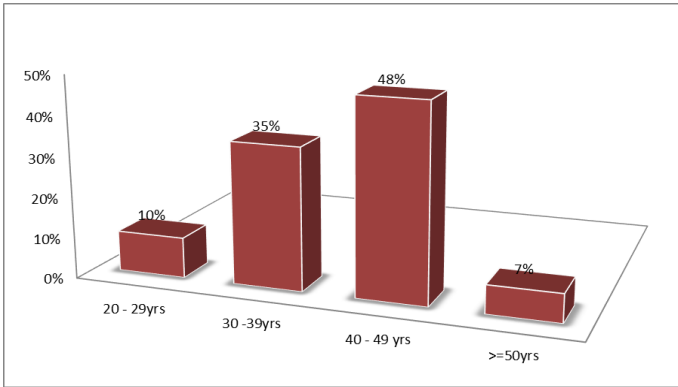
- Postmenopausal women, pregnant women, different types of abortion
- Patients lost to follow up from treatment and who refused diagnostic biopsy.

Relevant clinical data regarding age, pattern and duration of abnormal bleeding, menstrual history, obstetric history, physical and gynaecological examination findings, laboratory investigation results, sonological reports, hysteroscopic findings and histopathological reports were obtained. Uterine assessment was performed using a trans-vaginal or trans-abdominal ultrasound. In case of any intrauterine abnormalities, further examination such as hysteroscopy was performed to explore uterine cavity. An office endometrial biopsy was planned for patients over 40 years and those at higher risk of endometrial cancer: nulliparous, high BMI (30 kg/m²), PCOS, diabetic, family history of hereditary non-polyposis colorectal cancer syndrome and when treatment failed to stop AUB to rule out any malignant aetiology.

Statistical analysis

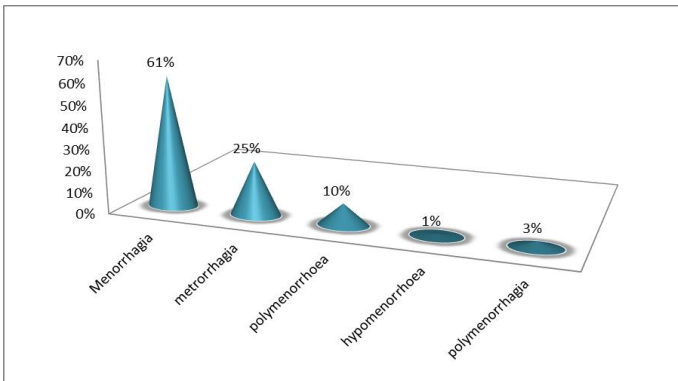
Data were entered in Microsoft Excel and managed in SPSS version 16. Analysis was done in the form of percentages and proportions and represented as tables and figures where necessary. AUB was classified as per PALM-COEIN classification.

Results



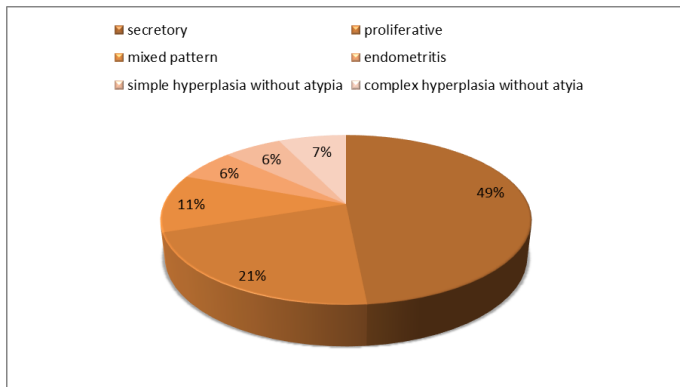
Graph 1: Age distribution of AUB Patients

Highest incidence is found in age groups of year between 40-49 years of age followed by 30-39 years, then 50 years and above.

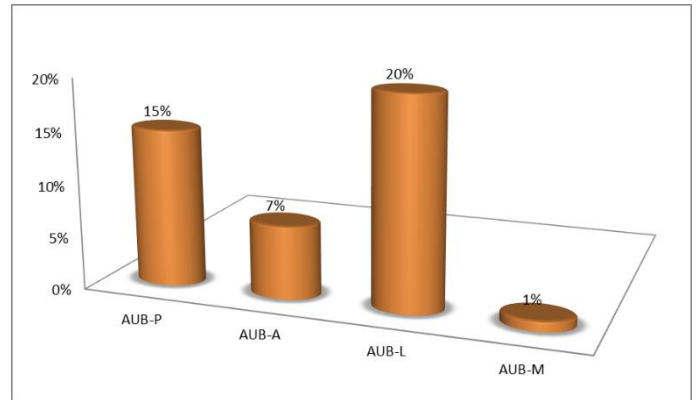


Graph 2: AUB different patterns

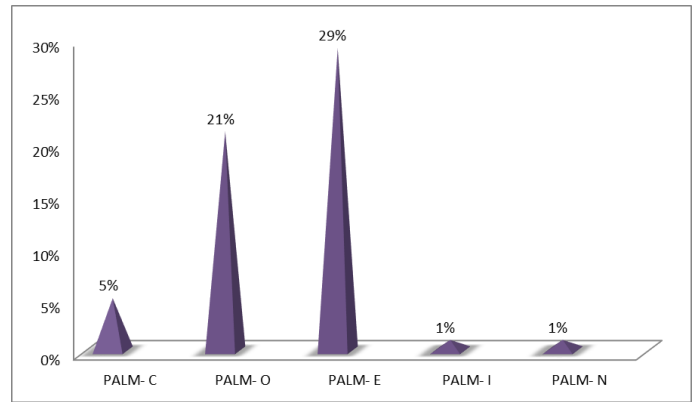
The most common pattern found was menorrhagia followed by metrorrhagia.



Graph 3: Histological patterns of endometrial biopsy reports.



Graph 4 Incidence of PALM cases



Graph 5: Incidence of COEIN cases.

Discussion

The study was undertaken to stratify the causes of AUB based on PALM COEIN classification and to correlate the clinical and histopathology features so as to know the precise etiology of AUB for successful management of AUB.

The routine non-invasive investigations for abnormal uterine bleeding include complete blood count, platelet count, prothrombin time (PT), Activated partial thromboplastin time (APTT) and liver function test to rule out any coagulation and bleeding disorders. Thyroid function test, follicle stimulating hormone (FSH), leuteinizing hormone (LH), serum prolactin levels are done to rule out any endocrine causes. The next step in the work up of AUB is trans-abdominal pelvic ultrasound (USG) or trans-vaginal ultrasonography and tissue sampling^{5,6,7}. Dilatation and curettage can be a diagnostic as well as therapeutic procedure.⁹ To rule out pregnancy, serum or urine HCG testing is important. It is mandatory to exclude pregnancy before starting work up of abnormal uterine bleeding.

Present study significantly shows that the incidence of menstrual disorders increases with advancing age. A similar incidence was reported by Yusuf et al⁸ and Muzaffar et al⁹ in their study of endometrium. In 41- 50 yrs phase, cycles shorten or prolong and often become anovulatory due to a decrease in the number of ovarian follicles and the estradiol level. Finally, there is a disbalance in hypothalamo-pituitary -ovarian axis leading to rise in serum FSH level.

The bleeding in the proliferative phase and in the secretory phase

may be due to anovulatory cycles and ovulatory dysfunctional uterine bleeding, respectively. . Endometrial hyperplasia is thought to be precursors of endometrial carcinoma. Risk increases gradually from simple hyperplasia without atypia to its maximum risk in complex hyperplasia with atypia¹⁰. The incidence of benign endometrial polyps in this study was high in 41-50 years age group. Due to normal cycling endometrium, endometrial polyp spontaneously regresses which leads to its low incidence in young women. In present study we saw that polyp with anovulation was the cause of menometrorrhagia. Polyp present with irregular cycles and anovulation leading to prolonged bleeding after a long gap of amenorrhoea. We can see that multiple factors can be involved to cause AUB in a single patient to cause AUB. Forgotten IUCD for a long time can cause heavy menstrual bleeding. It can cause chronic inflammation and endometritis leading to prolonged and heavy flow during menstruation. It comes under the category of AUB-I.¹¹

Conclusion

It helps us in understanding various etiological causes of AUB and can be used by clinicians to facilitate comparisons and research.

After proper classification of AUB by PALM-COEIN, patients can be treated medically or surgically according to the cause leading to better success rate. After complete work up of patients of abnormal uterine bleeding, full history and diagnosis of the disease can be summarised in one word as per PALM-COEIN and management can be done in a better way.

References

1. Doraiswami S, Johnson T, Rao S, Rajkumar A, Vijayaraghavan J, Panicker VK. Study of endometrial pathology in abnormal uterine bleeding. *J Obstet Gynaecol India*. 2011; 61(4):426-30.
2. Qureshi FU, Yusuf AW. Distribution of causes of abnormal uterine bleeding using the new FIGO classification system. *J PMA*. 2013; 63(973).
3. Templeman C, Marshall SF, Ursin G, Horn-Ross PL, Clarke CA, Allen M et al. Adenomyosis and endometriosis in the California Teachers Study. *Fertil Steril*. 2008; 90(2):415-24.
4. Weiss G, Maseelall P, Schott LL, Brockwell SE, Schocken M, Johnston JM. Adenomyosis a variant, not a disease? Evidence from hysterectomized menopausal women in the Study of Women's Health Across the Nation (SWAN). *Fertil Steril*. 2009; 91(1):201-6.
5. Taran FA, Weaver AL, Coddington CC, Stewart EA. Characteristics indicating adenomyosis coexisting with leiomyomas: a case control study. *Hum Reprod*. 2010; 1177-82.
6. Hoffman BL. *Williams Gynecology*. 2nd ed. Mc Graw Hill, 2012, 247.
7. Perveen S, Perveen S. Endometrium histology in abnormal uterine bleeding. *Q Med Channel*. 2011; 17(4):68-70.
8. Yusuf NW, Nadeem R, Yusuf AW, et al. Dysfunctional uterine bleeding. A retrospective clinicopathological study over 2 years. *Pak J Obstet Gynaecol*. 1996; 9:27-30.
9. Muzaffar M, Akhtar KAK, Yasmin S, Rehman M, Iqbal W, Khan MA. Menstrual irregularities with excessive blood loss: a clinico-pathologic correlation. *J Pak Med Assoc*. 2005; 55(11): 486-9.
10. Silverberg SG. Problems in the differential diagnosis of endometrial hyperplasia and carcinoma. *Modern Pathol*. 2000; 13(3):309-7.
11. Gredmark T, Kvint S, Havel G, Mattsson LÅ. Histopathological findings in women with postmenopausal bleeding. *BJOG: An International J Obstetr Gynaecol*. 1995; 102(2):133-6.